



General histomorphology of testis of domestic goat (*Capra aegagrus hircus*)

Payal Garg*, Rajnish Sharma, Jitender Bhardwaj, Priyanka

Department of Zoology, Kurukshetra University, Kurukshetra, Haryana, India

Abstract

Agriculture is the backbone of the Indian economy, where livestock contributes significantly to rural livelihoods. Goats (*Capra aegagrus hircus*) are particularly important for milk, meat, and leather production, yet limited studies address their reproductive histology. The present study investigated the general histomorphology of the domestic goat testis using Hematoxylin and Eosin (H&E) staining. Histological analysis revealed well-organized seminiferous tubules encased by a distinct basement membrane. The seminiferous epithelium displayed orderly layers of germ cells: spermatogonia localized at the basal region, spermatocytes in the middle zone, and spermatozoa oriented toward the lumen, confirming active spermatogenesis. Sertoli cells were interspersed within the tubules, providing structural and nutritional support. The lumen of the tubules was clearly defined, indicating ongoing sperm release. Interstitial tissue showed clusters of polyhedral Leydig cells with vesicular nuclei, confirming steroidogenic activity essential for androgen secretion. Microphotographs further demonstrated intact cellular organization with no disruptions in spermatogenic arrangement, suggesting healthy testicular function. The results highlight the functional significance of seminiferous tubules and Leydig cells, offering valuable reference material for future research on fertility, breeding management, and testicular pathology in goats.

Keywords: Goat, histology, testis, morphology, milk, meat

Introduction

Agriculture is the mainstay of the Indian economy. Agriculture and allied sectors contribute nearly 22 per cent of the Gross Domestic Product (GDP) of India (Sachdeva, 2007) ^[1]. As the agricultural industry remains the prime source of national revenue, there has been an increased use of pesticides to enhance crop production. Indian agriculture has witnessed remarkable growth over the past few decades. Following independence, the Indian population grew at a much faster rate than food production. To meet the rising demand for dairy and other animal-based products, farm animals such as goats, sheep, cows and buffaloes play a crucial role in sustaining the economy by providing milk, meat, fiber and leather. Among these animals, goats (*Capra aegagrus hircus*) hold significant importance in the Indian agricultural system. India is home to numerous indigenous goat breeds that contribute to rural livelihoods and food security. Some notable Indian goat breeds include Jamunapari, Beetal, Barbari, Sirohi, Osmanabadi and Malabari. Each breed is adapted to different agro-climatic conditions, making them valuable for diversified agricultural practices.

In North India, particularly in Haryana, goat farming is a vital aspect of livestock management. Haryana has a semi-arid to arid climate, which is well-suited for rearing goats due to their high adaptability to harsh environmental conditions. Goat farming in Haryana serves as an essential livelihood for small-scale and marginal farmers, providing them with a sustainable source of income through milk and meat production. The prominent breeds found in Haryana include the Beetal and Jakhrana, which are well known for their high milk yield and superior adaptability.

Despite the availability of extensive research on laboratory animals, there is a lack of studies focusing on the testicular histomorphology of farm animals such as goats. The testis, being the male gonad, is essential for the process of spermatogenesis and reproductive function. The male

reproductive system, particularly the testis, plays a fundamental role in reproductive physiology. The testes are the primary sex organs responsible for spermatogenesis and hormone production. The testes of goats, like other mammals, are paired organs located in the scrotum and serve as the site for sperm production and maturation. The testicles are enclosed within a dense fibrous capsule known as the tunica albuginea. Beneath this capsule lies the testicular parenchyma, which is composed of 250-350 lobules. These lobules are separated by connective tissue septa (Septula testis) that extend from the mediastinum testis, where the lobules ultimately drain into the epididymis. Each lobule consists of one or more seminiferous tubules, the functional units responsible for spermatogenesis. Understanding the histological structure of the goat testis can provide insights into its functional significance and potential implications for breeding and reproductive efficiency. The present investigation aims to analyze the general histomorphology of the testis of Caprine goat (*Capra aegagrus hircus*). External appearance of male reproductive system of goat include two testicles, which are typically of similar size. However, in sharks, the right testicle is usually larger and in many bird and mammal species, the left testicle may be the larger. Primitive jawless fish have only a single testis located in the midline of the body. In mammals, the testes are often contained within an extension of the abdomen called the scrotum. Each testis is covered by a fibrous capsule called the tunica albuginea and is divided by partitions of fibrous tissue from the tunica albuginea into 200 to 400 wedge-shaped sections or lobes. Within each lobe, there are 3 to 10 coiled tubules called seminiferous tubules, which produce sperm cells. The partitions between the lobes and the seminiferous tubules converge in one area near the anal side of each testis, forming what is called the mediastinum testis. The seminiferous tubules are lined with a layer of cells (germ cells) that, from puberty to old age, develop into sperm cells

(also known as spermatozoa or male gametes). The developing sperm travel through the seminiferous tubules to the rete testis, located in the mediastinum testis, then to the efferent ducts and finally to the epididymis, where newly created sperm cells mature. The sperm then move into the vas deferens and are eventually expelled through the urethra and out of the urethral orifice via muscular contractions during ejaculation. Here, germ cells develop into spermatogonia, spermatocytes, spermatids and finally into spermatozoa through the process of spermatogenesis. The gametes contain DNA necessary for the fertilization of an ovum.

Sertoli cells, which make up the true epithelium of the seminiferous tubules, are critical for supporting germ cell development into spermatozoa. Sertoli cells secrete inhibin and also produce testicular fluid, which contains a protein that binds to and concentrates testosterone, an essential hormone for sperm development. These cells obtain nutrients from nearby capillaries despite being avascular. Between the seminiferous tubules, Leydig cells (also called interstitial cells) are responsible for producing and secreting testosterone and other androgens, which are crucial for sexual development and puberty. These hormones contribute to secondary sexual characteristics such as facial hair, sexual behavior, libido and the support of spermatogenesis. Testosterone also plays a role in controlling testicular volume. Immature Leydig cells, along with macrophages and epithelial cells, are also present in the testicular interstitium.

Material and Methods

Testis samples from freshly slaughtered mature caprine (goats) were collected from slaughter houses near Kurukshetra and immediately transferred to the laboratory in a collection jar containing normal saline to maintain tissue viability. Upon arrival, the tissues were thoroughly cleaned and washed with fresh normal saline to remove any contaminants. After the washing process, the outer layer of the testes was carefully removed to expose the internal structure. The cleaned testes were then dissected into small, uniform pieces under sterile conditions to ensure precision and consistency for further analysis. The small sections of testicular tissue were subsequently cultured following the established experimental protocol to study their cellular composition and function. This process ensured the integrity of the sample for further biological and histological examinations.

Preparation of Histological Slides

The tissue was harvested after the stipulated time and processed for histological slide preparation. For histological slides, the testis was fixed in aqueous Bouin's fixative for 24 hours. The tissue was then washed in running tap water for 3-4 hours.

Next, the specimens were dehydrated in various grades of alcohol. After proper dehydration, the specimens were embedded in paraffin wax at 58-60°C. The tissue was then serially sectioned at 5 µm thickness.

The sections were stained with hematoxylin for 2-3 minutes and allowed to develop for 5-7 minutes in tap water. After dehydration in 70% ethanol, the sections were stained with eosin for 40-50 seconds. The slides were then washed in 70% ethanol, further dehydrated in 90% and absolute alcohol, cleared in xylene, and mounted in DPX.

Each section was examined under a light microscope to study the morphological characteristics of the tissue.

Staining Protocol for Histological Slides:

Following are the sequencing steps of the staining protocol for histological slides:

- Place the slide in xylene (5-7 minutes)
- Transfer to 100% alcohol (5-7 minutes)
- Transfer to 90% alcohol (5-7 minutes)
- Transfer to 70% alcohol (5-7 minutes)
- Transfer to 50% alcohol (5-7 minutes)
- Transfer to 30% alcohol (5-7 minutes)
- Rinse in distilled water (5 minutes)
- Stain with hematoxylin (2 minutes)
- Rinse in tap water (5-7 minutes)
- Transfer to 30% alcohol (5-7 minutes)
- Transfer to 50% alcohol (5-7 minutes)
- Transfer to 70% alcohol (5-7 minutes)
- Stain with eosin (40-50 second)
- Dip in 70% alcohol (1-2 dips)
- Transfer to 90% alcohol (5-7 minutes)
- Transfer to 100% alcohol (5-7 minutes)
- Place in xylene (5-7 minutes)
- Mount in DPX for permanent preservation.

Results

The histomorphological analysis of the testis of the domestic goat (*Capra aegagrus hircus*) reveals a well-organized structure consisting of seminiferous tubules, interstitial tissue, and various germ and somatic cells. Microphotographs illustrate the general histology, showing that the seminiferous tubules (Figure 1) are surrounded by a basement membrane and contain different stages of germ cells, including spermatogonia at the basal region (downward arrow), spermatocytes in the middle portion, and mature spermatozoa in the lumen. Sertoli cells, which provide support and nourishment to the developing sperm cells, are interspersed within the tubules.

The interstitial tissue surrounding the seminiferous tubules houses clusters of Leydig cells, which are responsible for testosterone production. The polyhedral structure of Leydig cells with vesicular nuclei is indicative of their steroidogenic activity, crucial for maintaining spermatogenesis. The basement membrane provides structural support to the tubules, while the presence of a well-defined lumen confirms ongoing sperm production.

Hematoxylin and Eosin (H&E) staining effectively differentiates cellular components, allowing for clear visualization of spermatogenic cells. The distinct arrangement of germ cells in the seminiferous epithelium indicates an active and healthy spermatogenic process. The observed microphotographs show no significant disruptions in cellular organization, suggesting normal testicular function.

Discussion

These findings align with existing literature on goat testicular histology, reinforcing the role of seminiferous tubules in sperm production and the function of Leydig cells in androgen secretion. The structural integrity of the testicular tissue, as evident in the microphotographs, confirms the efficiency of spermatogenesis in the domestic goat.

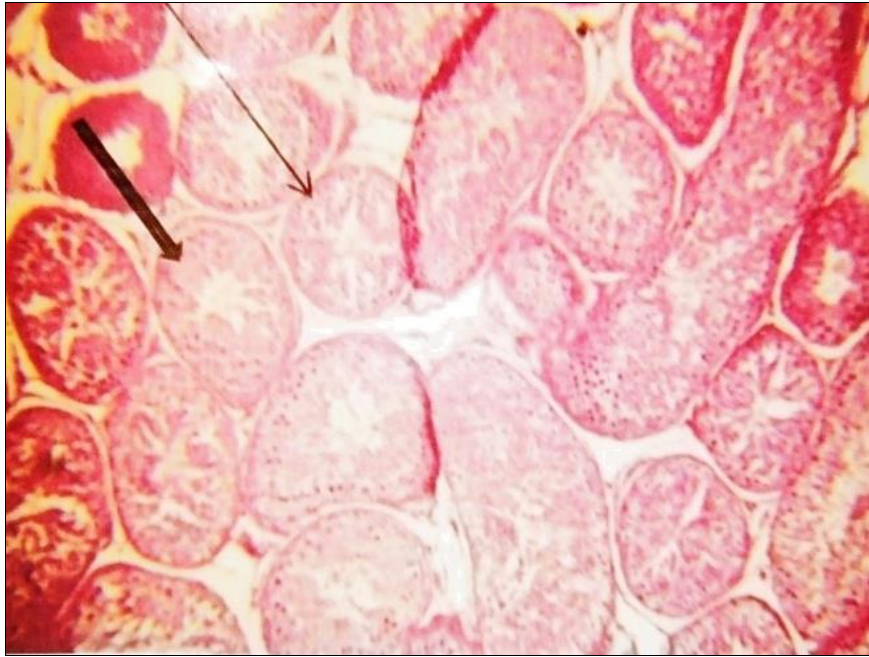


Fig 1: Microphotograph of goat testis showing the normal structure of seminiferous tubules (arrow), with an abundance of spermatogonia (downward arrow) and spermatozoa cells (100X)

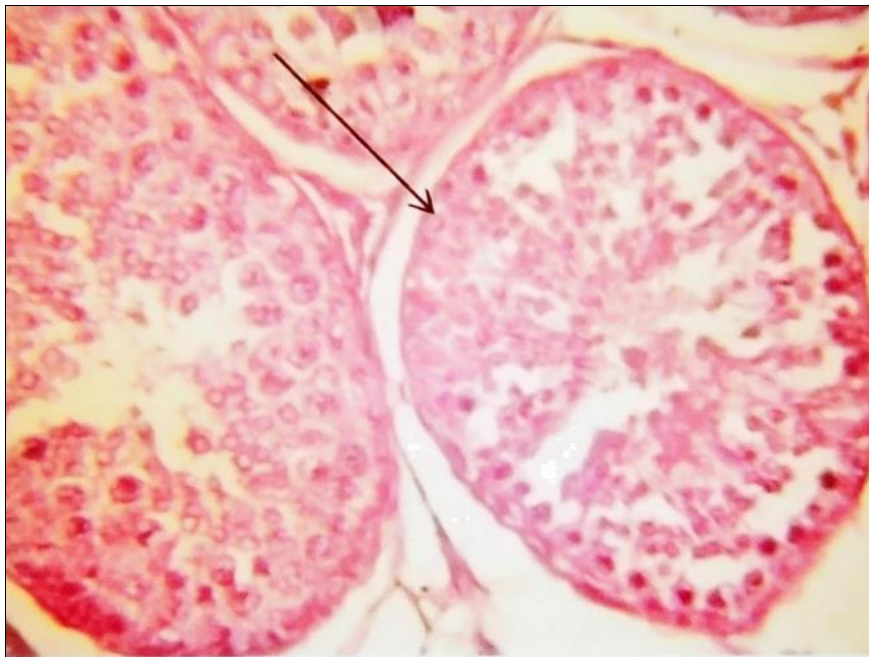

Fig 2: Microphotograph of goat testis showing spherical-shaped seminiferous tubules (arrow), stained with H&E (400X).

Conclusion

The present study highlights the general histomorphology of the testis of the domestic goat (*Capra aegagrus hircus*), emphasizing its well-defined seminiferous tubules, interstitial tissue, and cellular organization. The presence of spermatogonia, spermatocytes, and mature spermatozoa within the seminiferous tubules indicates active spermatogenesis. Sertoli cells provide structural and nutritional support, while Leydig cells in the interstitial tissue contribute to testosterone production. The H&E stain effectively differentiates these cellular components, confirming normal testicular architecture. The observations align with existing literature on goat reproductive biology, reinforcing the crucial role of testicular histology in fertility. These findings contribute valuable insights into caprine reproductive anatomy and may serve as a baseline for

further studies on testicular function and pathology in domestic goats.

Reference

1. Sachdeva R. Agriculture and Economic Growth in India. Economic and Political Weekly, 2007;42(6):563-568.
2. Hafez ESE. Reproduction in Farm Animals. Lippincott Williams & Wilkins, 2000, 33-44.
3. Senger PL. Pathways to Pregnancy and Parturition. Current Conceptions, Inc. Ed. 2, 2005, 312-330.
4. Evans G, Maxwell, WMC. Salamon's Artificial Insemination of Sheep and Goats. Butterworths, 1987.
5. Sharma RK, Taneja VK. Reproductive Physiology of Goats. Indian Veterinary Journal, 1987;71(4):345-351.