



Anatomical, histological and histochemical structure of retina in little ringed plover *Charadrius dubius*

Hamid Hassan Hamid¹, Nazar Mohammed Hasan¹, Ameer M Taha²

¹ Biology Teacher, Department of Biology Education College for Pure Sciences, Nenevah Directorate of Education, Mosul, Iraq

² Department of Biology, Education College for Pure Sciences, Mosul University, Mosul, Iraq

Abstract

The current research aimed to identify the anatomical, histological and histochemical structure of the retina one of the wild birds in Iraq, which is the little ringed plover, *Charadrius dubius*. To achieve this goals, ten plover birds were used, and after performing the dissection and histological preparation, four histological and histochemical stains were used to identify the results. The results showed that the retina can be divided anatomically into four regions: dorsotemporal, dorsonasal, ventrottemporal, and ventronasal. These regions differ in terms of thickness and cell density. Histologically, the retina is divided into eight distinct layers in all its regions as well as two limiting membranes. These layers are the pigmented epithelial layer, which appears to be composed of a single row of epithelial cells that are cubic to columnar in shape. The photoreceptor cell layer appeared to consist of a single row of cells of two types: rods and cones, which differ in external appearance and function. Cones, in turn, were of two secondary types: single cones and double cones. All types of photoreceptor cells were composed of two segment: outer and inner segment, which was composed of two parts: ellipsoid region and the myoid region. The remaining layers of the retina, known as the inner retina, appeared to differ in thickness between different areas of the retina. The results also showed that the retina in this bird is avascular. The retina contained several areas of specialization. Two fovea appeared in the dorsotemporal and ventronasal regions. One area centralis and two visual streak appeared in the ventrottemporal and dorsonasal regions, respectively. The study concluded that the structure of the retina is advanced in this bird and that multiple areas of specialization enable the bird to have a strong ability to see food and prey from enemies.

Keywords: Retina, photoreceptors cells, little ringed plover, fovea, rods, cones

Introduction

Birds are distinguished by having highly efficient eyes, more than other vertebrates, as they can distinguish distances well from long distances, which makes it easier for them to escape from enemies and obtain food by relying on their great ability to see. This high degree of capacity for specialized visual processing makes them excellent candidates for studying their visual structures (Al-Sakqaid, 2016).

The retina is the important and visible part of the eye in birds and other vertebrates. It is the light-sensitive part (Harmening and Wagner, 2011 ^[19]; Kardong, 2012) ^[22]. It is a sensitive and complex tissue consisting of several layers and many cells, which is responsible for absorbing light rays and converting them into special signals that are transmitted to the visual part of the brain as nerve impulses to transform them into a visual image (Treuting and Dintzis, 2012) ^[40].

One of the most important layers of the retina is the layer of photoreceptor cells, which contains types of photoreceptors, which consist of two basic types of cells: rods, which are specialized for night vision, and cones, which are specialized for day vision. The bird retina contains three types of photoreceptor cells: rods, single cones, and double cones (Mitkus, 2017) ^[28]. Visual acuity in diurnal birds such as hawks, eagles, and gulls is high because the retina is rich in cones, while the retina in nocturnal birds such as owls is characterized by its sensitivity to high light because it contains an abundance of rods (Harmening and Wagner, 2011 ^[19]; Kardong, 2012) ^[22].

Visual pigments are found in photoreceptors. Rod cells contain a visual pigment known as Rhodopsin, which is known as visual violet pigment. The visual pigment in cone cells is called iodopsin, and in the cones it is responsible for seeing three colors: blue, green, and red. Both Iodopsin and Rhodopsin contain opsin, which in rods is known as scotopic and is responsible for vision in dim light (night vision), while opsin in cones is known as photopic and is responsible for vision in bright light (day vision). Opsin in the retina is linked to vitamin A. When these pigments absorb light, the shape of these molecules in the retina changes, and then the photoreceptor cell is stimulated to produce a nerve impulse that is transmitted through the optic nerve to the brain (Ross and Pawlina, 2011 ^[34]; Kardong, 2012) ^[22]. While the double cones contribute to color visual tasks in addition to non-color visual tasks such as pattern recognition and motion detection (Osorio *et al.*, 1999) ^[31]. The retina is characterized by containing distinct areas known as retinal specializations. The visual resolution in these areas is very high, and is superior to the rest of the retinal areas. In addition, these areas have other functions, such as improving motion detection. In birds, these areas are represented by the fovea, the area centralis, and the visual streak (Moore *et al.*, 2017) ^[29].

The number and types of photoreceptors in these areas are greater than those in other areas of the retina and even in the human retina (Harmening and Wagner, 2011 ^[19]; Kardong, 2012) ^[22]. One of the most studied retina specializations in vertebrates is the fovea, which is characterized by an

abundance of photoreceptor cells, especially cones, and an increase in the number of cones indicates an increase in visual resolution in this region of the retina (Moore *et al.*, 2016) [30]. In this region of the retina, the inner layers are displaced in the center of the fovea, forming what is called the fovea, which is devoid of rods and completely characterized by the presence of a high density of cones (Moore *et al.*, 2017) [29].

Birds are divided, in general, based on the presence or absence of a fovea into birds without a fovea, as they lack a fovea but contain an area centralis or visual streak, such as most domestic birds and some water birds. The second type of bird is monofoveate, as it has one fovea that may be central, as in most birds such as owls and swifts, regardless of the presence or absence of the visual streak. As for the third type, they are bifoveate birds, as there is a main central fovea and a temporal fovea, in the presence or absence of the visual streak, for example eagles, hawks, and other flying birds (Bayón *et al.*, 2007) [12].

As for area centralis, this area is represented by a marked increase in the density of retinal neurons (photoreceptors and ganglion cells). This specialization is found in different areas of the retina. It may be central, dorsal, ventral, or it may be temporal or nasal. The retina contains one or more area centralis, and this area has an important role in making vision highly accurate. The species of birds in which there is a density of ganglion cells in specialized areas are, there is also a density of photoreceptor cells in the central retina (Rahman *et al.* 2008 [33]; Moore *et al.* 2017) [29].

While visual streak is defined as a thickening and increase in the density of photoreceptor cells as well as ganglion cells. This specialization is involved in highly sensitive vision and is assumed to have more than one function depending on the types of ganglion cells that occupy the visual chain (Moore *et al.*, 2017) [29]. Hart (2004) mentioned that this specialization is in the form of transverse bands extending from the dorsal retina to opposite the top of the pecten.

Therefore, this research aimed to identify the anatomical and histological as well as the histochemical structure of the retina in one of the wild birds, the little ringed plover, *Charadrius dubius*.

Material and methods

Ten adult birds of the little ringed plover, *C. dubius*, were collected from different areas of the city of Mosul / Iraq. They were transferred to the Anatomy and Histology Laboratory at the College of Education for Pure Sciences, University of Mosul / Iraq. Birds were dissected after being anesthetized by chloroform. The eyes were extracted after removing the heads. The eyes were fixed after dividing the eyes into four parts from the temporal, nasal, dorsal and ventral sides. Fixation was done using buffered formalin solution for 48 hours (Suvarna, 2019) [36]. After fixation, the samples were washed with running water for 30 minutes to remove traces of fixation (Taha and Abed, 2021). Water was removed through a series of descending concentrations of ethyl alcohol for 15 minutes for each concentration (Hamid and Taha, 2021). Then the samples were cleared with xylene for 10 minutes. The samples were embedded in paraffin

wax, which was also used to make wax molds. Using a rotary microtome, the templates were cut into slices with a thickness of 5µm, which were stained with the following stains: hematoxylin and eosin (H&E) stain, Masson trichrome stain (M), which was used to study the general structure of the retina, Periodic Acid Schiff (PAS) technique to detect carbohydrates, and toluidine blue stain (TB) (Taha, 2021). Finally, they were examined and photographed using a compound light microscope (AlThanoon and Taha, 2022).

Results

The results showed that the thickness of the retina in this bird varies in different regions of the retina and ranged between (197.146 - 371.764) micrometers (Figures 1a, 1b). The retina can be divided anatomically into four regions: dorsotemporal, dorsonasal, ventrotemporal, and ventronasal (Figures 1a, 1b, 1c, 1d, 1e). As is the case in other birds and other vertebrates, the retina appears histologically composed of eight layers and two specific membranes. These eight layers differ in thickness in the previously mentioned retinal areas. These layers, from outside to inside, are: pigment epithelial cells (EP), which are one row of cells that are cubic to columnar in shape with a centrally located spherical nucleus. These cells are characterized by having cytoplasmic processes (CP) that form long, dense floccule that reach the middle of the photoreceptor cells (Figures 2, 3, 4).

The second layer is the layer of photoreceptor cells (RC), which contained from two basic types of cells: rods (R) and cones (C). The number and density of these cells varies from one area to another within the retina of this bird. The ratio of rods to cones was 1:4. The rods appeared arranged in one row with the cones. Rods and cones are bipolar neurons that are divided into two parts: the first is an external part known as the outer segment, which is cylindrical in shape in rods and conical in shape in cones. This outer segment connects with the processes of the pigment epithelial cells. While the inner part of these cells is known as the inner segment, which consists of two parts: the ellipsoid region and the myoid region (Figures 3,4,5,6,7). The cones are characterized by being in more than one kind in the retina of this bird. The first kind is known as single cones, which are single cells. While the second form is known as double cone (DC), which are composed of two conjoined cells, each of which is known as a unit, but they are not equal in size and length. The thicker and longer unit is known as the principle unit while the other is known as the accessory unit (Figures 3, 4, 5, 6, 7). The outer and inner segments of the photoreceptor cells and the nuclei of these cells are separated by a structure known as the outer limiting membrane (OL), which appears clear and thick in some areas and is not visible in other areas of the retina (Figures 3, 4, 5, 6, 7).

The third layer is the outer nuclear layer (ON), which consists of the nuclei of photoreceptor cells. This layer showed differences in its thickness, size, and number of rows between different regions of the retina. The number of its rows ranged between (3-5) rows. The nuclei of the rods are in the inner rows, while the nuclei of the cones are in the upper rows. They are generally large in size and oval in shape

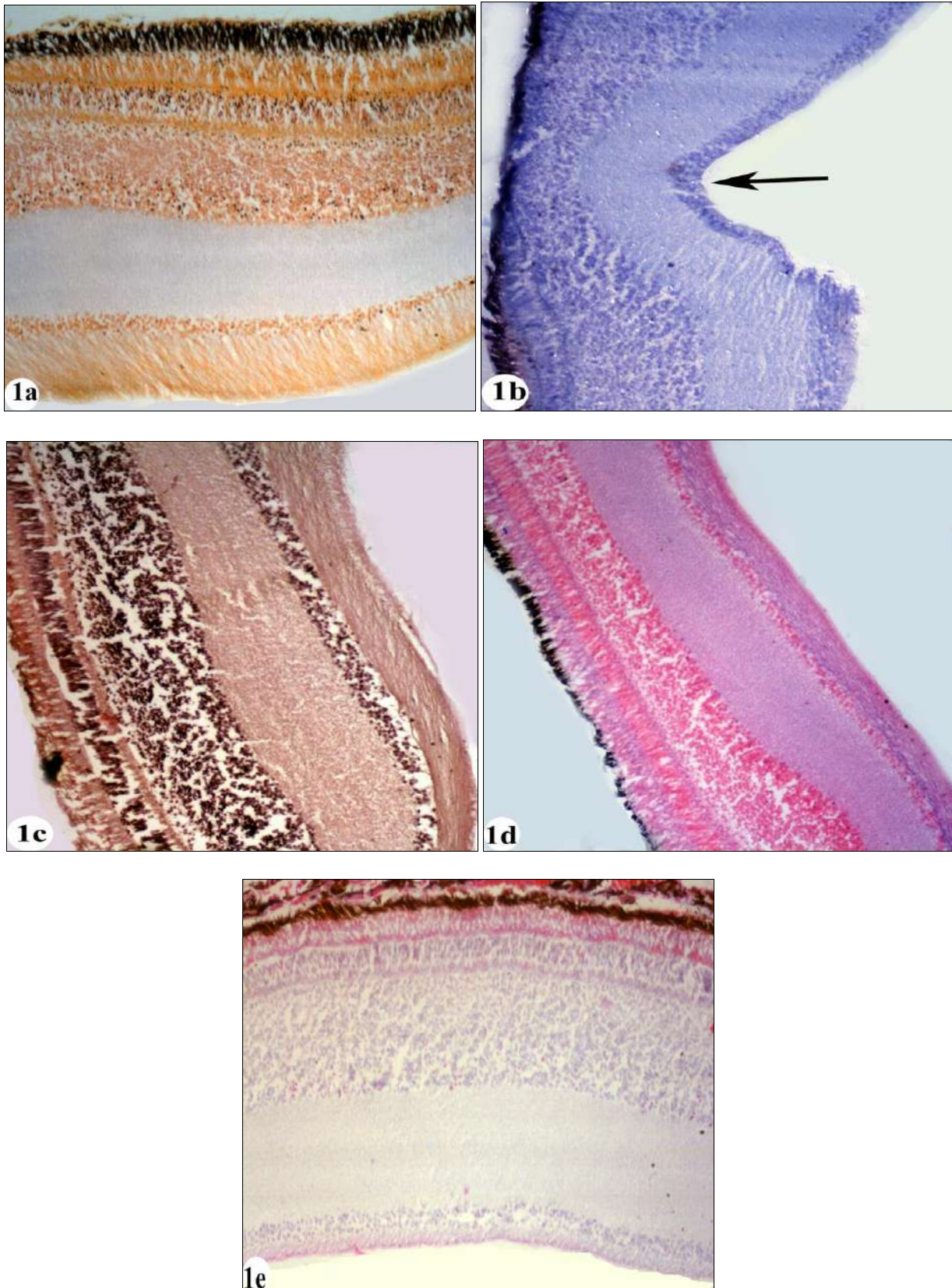


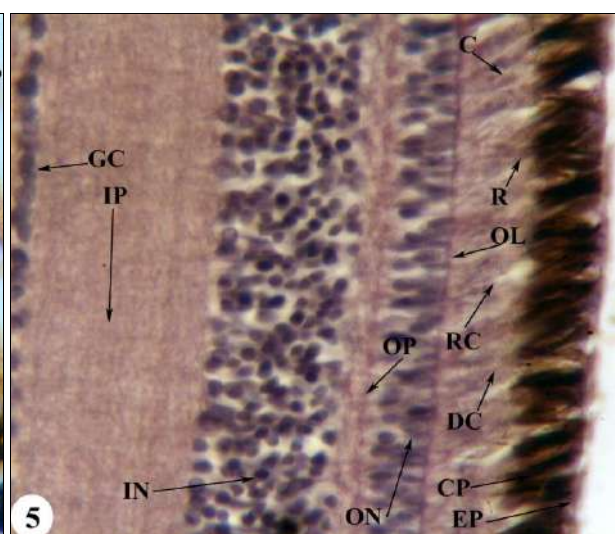
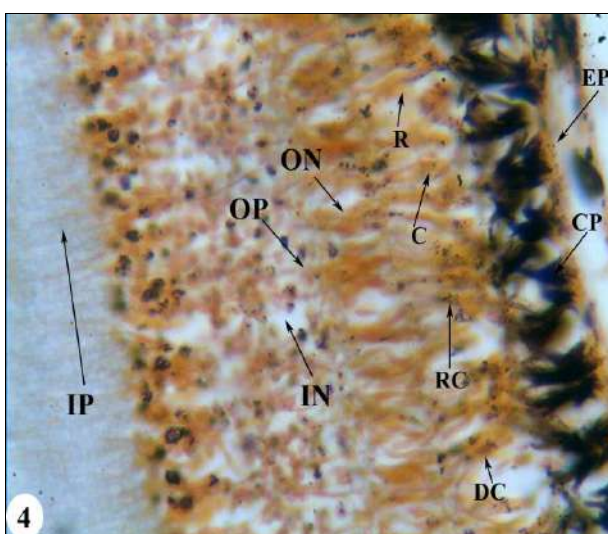
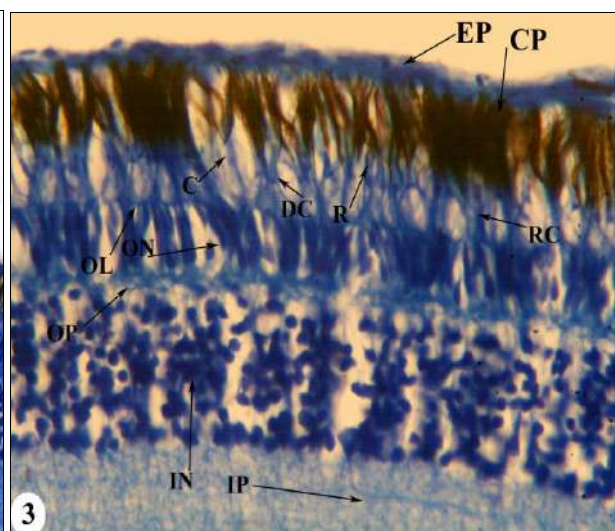
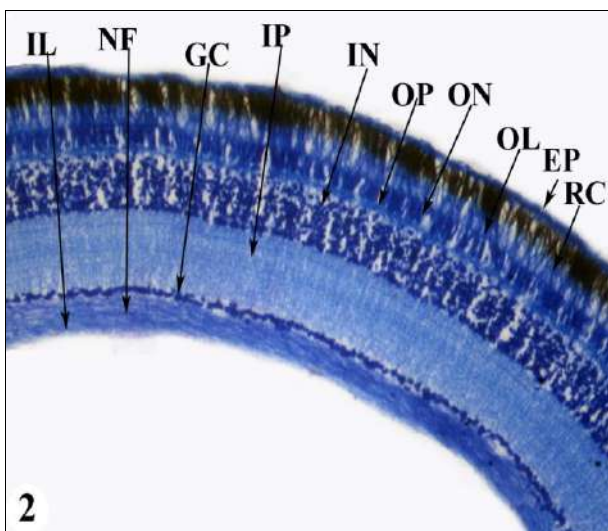
Fig 1: Sections in the retina in the little ringed plover. (a) the retina in the dorsotemporal region (visual streak). M Stain 40X. (b) the retina in the dorsotemporal region, the arrow = fovea, TB Stain 40X. (c) the retina in the dorsonasal region. PAS Stain, 40X. Figure (d) the retina in the ventrotemporal region, H&E Stain 40X. (e) the retina in the ventronasal region (visual streak), H&E Stain 40X.

(Figures 3, 4, 5, 6, 7). The fourth layer is the outer plexiform layer (OP), which represents the part of the retina where the axons of photoreceptor cells meet the dendritic projections of neurons in the inner retinal layers. This layer was thicker in the specialized areas of this bird's retina than in the rest

of the retina. The layer following the outer plexiform layer is the inner nuclear layer (IN), which consists of three types of neurons: horizontal cells, bipolar cells, and amacrine cells. The last type is support and nourishing cells known as Müller glial cells. The number of rows of cells in this layer

varies depending on the regions of the retina, and the number of rows ranges between (3-16), and the cells of this layer are closely packed. The horizontal cells are in the upper rows of this layer, followed by bipolar cells, then amacrine cells, which are large in size compared to the other two types. While Müller cells are randomly distributed among the rows of cells in this layer (Figures 3,4,5,6,7,8,9). The sixth layer is the internal plexiform layer (IP), which consists of the axons of neurons in the outer nuclear layer with the dendritic projections of neurons in the later layer of the retina. The fibers in this layer are myelinated and non-myelinated fibers. This layer is thick in some areas, but it is thicker in the specialized areas of retina. The seventh layer is the ganglion cell layer (GC), which is characterized as multipolar cells that differ in size, number of rows, as well as the size of the nucleus. The number of rows in this layer ranged between (1-5) rows. The rows of these cells are higher in the areas of specialization that will be mentioned later. These cells are closely packed. The last layer is the layer of nerve fibers (NF), which represents the axons of the ganglion cells that extend towards the center of the eyeball to gather and form the optic nerve (Figures 6,7,8,9). As is the case with the rest of the layers of this bird's retina, this layer's thickness varied in different areas of the retina. These fibers are perpendicular to the internal limiting

membrane. Ganglion cells migrating from the ganglion cell layer towards this layer also appeared in some areas of the retina. The last part of this bird's retina is the inner limiting membrane (IL), which lines the layer of nerve fibers from the inside, which was straight and thick in most areas of the retina and devoid of any specialization (Figures 6,7,8,9). One of the important results that was observed in the retina of this bird is that it is free of blood vessels, meaning that the retina in this bird is avascular. As for retinal specialties, which are distinct areas of the retina in which visual resolution is extremely high. The first area of specialization to appear in the retina of this bird is the fovea. Two fovea appeared in this bird, the first in the dorsotemporal region and the other in the ventronasal region. The first has a deep slope and the second has a gradual slope. In these two areas (the fovea), a reduction in a number of retinal layers appears, with the exception of the first layers of the retina (Figure 1b, 10). An Area centralis also appeared in the ventrotemporal region and is characterized by the density of all layers of the retina, especially the photoreceptor cell layer and the ganglion cell layer (Figure 11). The last specialty that appeared in the retina of this bird is the visual streak that appeared in the dorsonasal region and is characterized by



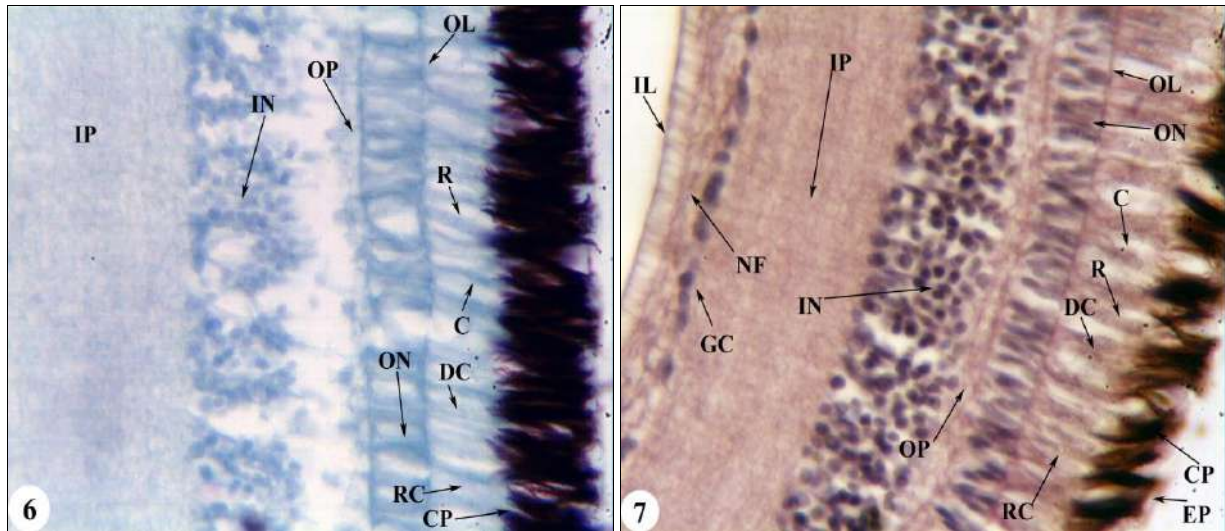


Fig 2: Section in the retina of the little ringed plover TB Stain, 10X. Figure (3): the retina in the dorsotemporal region. TB Stain 40X. Figure (4): the retina in the ventronasal region, M Stain 40X. Figure (4): the retina in the dorsotemporal region. PAS Stain, 40X. Figure (5) the retina in the ventrotemporal region, PAS Stain 40X. Figure (6): the retina in the ventronasal region, M Stain 40X. (7): the retina in the dorsotemporal region. PAS Stain, 40X. the density of the retinal layers, especially the pigment epithelial cells and photoreceptor cells. Also another one appeared in the ventronasal region (Figures 1a,1e).

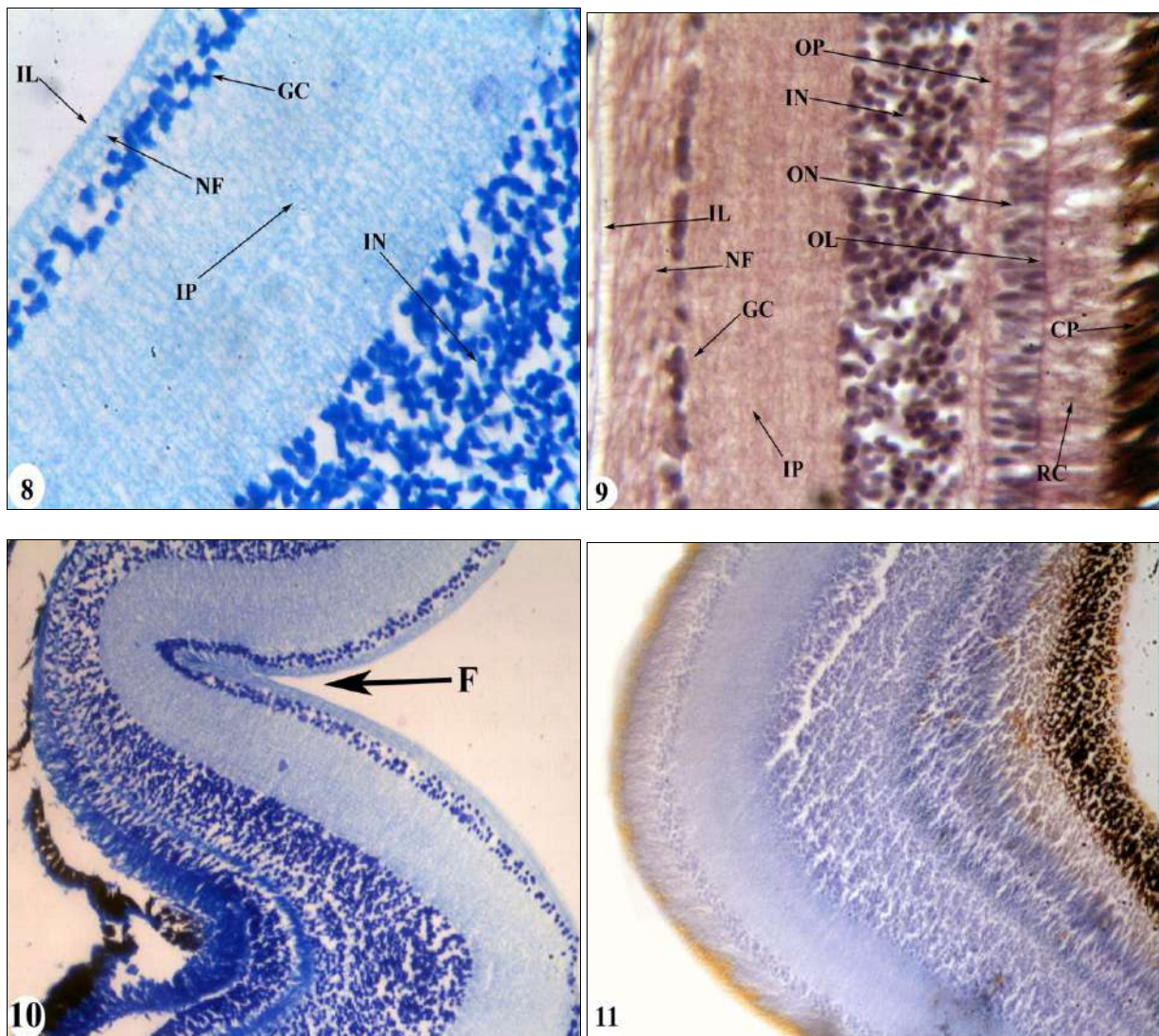


Fig 8: Section in the retina of the little ringed plover TB Stain, 10X. Figure (9): the retina in the dorsotemporal region. PAS Stain 40X. Figure (10): the retina in the ventronasal region, F= Fovea, TB Stain 10X. Figure (11): the retina in the ventrotemporal region (area centralis). M Stain, 10X.

Discussion

The retina in this bird appeared to vary in thickness in different areas of the retina, which is what has appeared in many birds, such as starlings and sparrow hawk (Al- Araji, 2019). This difference in retinal thickness is due to the degree of density of photoreceptor cells and subsequent neurons in the other retinal layers (Abd and Al-Majeed, 2010) ^[1]. Collin (1997) explained that variation in retinal thickness is important in increasing areas of acute visual specialization and increasing high power of discrimination. The retina also appeared to consist of eight secondary layers and two membranes. The appearance of the retina with this histological structure and arrangement in layers also appeared in different types of vertebrates (Szabadfi *et al.*, 2015 ^[37]; Salem, 2016 ^[35]; Ali, 2016 ^[7]; Azab *et al.*, 2017 ^[11]; Abid, 2018) ^[3].

The layer of epithelial cells is located between the photoreceptor cell layer on the one hand and the choroid layer on the other hand. The cells of this layer appeared to be composed of a single row of cubic to columnar cells. As in other types of birds (Abid, 2018) ^[3]. The pigment epithelial cell layer is located between the photoreceptor cell layer on the one hand and the choroid layer on the other hand. The cells of this layer appeared to be composed of a single row of cubic to columnar cells, as in other types of birds (Abid, 2018) ^[3]. These cells have processes that extend toward the photoreceptor cells and are black in color due to the abundance of melanosomes. The presence of elongations is a general characteristic in vertebrates (Al- Juburi, 2014 ^[8]; Keeling *et al.*, 2018) ^[23]. The layer of pigment epithelial cells plays an important role in absorbing scattered light passing through the nerve layer and removing free radicals from it (Mescher, 2013) ^[25]. The elongations of these cells also phagocytize the discs of the outer segments falling from the photoreceptor cells (Michael, 2017) ^[26].

The results showed that the retina in this bird is double, meaning that it contains both rods and cones photoreceptors. This is what appeared in various birds (Al-Hamdany, 2012; Ali, 2016 ^[7]; Abid, 2018) ^[3]. The fact that the retina contains rods and cones is a distinctive feature of birds, as none of the previous studies indicated the existence of a species of bird that contains only one type of photoreceptor cell (Ali, 2016 ^[7]; Abid, 2018) ^[3]. The ratio of cones was higher than the ratio of rods, and the increase in the ratio of cones to rods indicates that this bird is active during the day, and the presence of rods in its retina indicates that it also has the ability to sense at night (Jones *et al.* 2007).

The rods in the retina of this bird are of one type, and this is what appeared in all the types of birds studied (Mirhish *et al.*, 2012). As for cones, they appeared in two types: single cones, which are similar in structure to rods in that they are composed of two outer and inner segments. The inner segment are divided into two parts: ellipsoid region and the myoid region. As for the double cones, they consist of two units, each unit representing an independent cell, but they are not equal in length and size, which is what appeared in many birds (Al-Hamdany, 2012 ^[6]; Wilby and Roberts, 2017) ^[41].

This outer nuclear layer consists of the nuclei of rods and cones. The results of the study showed that this layer varies in thickness and number of rows between different areas of the retina. The difference in the rows of this layer may be due to the difference in the density of visual cells in different regions of the retina (Treuting and Dintzis, 2012)

^[40]. The difference in the rows of this layer is affected by the light environment in which the animal lives (Abid, 2017) ^[4]. This outer plexiform layer of different thickness appeared in areas of the retina, and it represents the area of intertwining of the axons of cones and rods with the dendritic protrusions of cells coming from the inner nuclear layer, which also appeared in the rest of the birds (Abid, 2018) ^[3].

The results of the current study showed that the cells of the inner nuclear layer consist of four types of cells, three of which are nervous cells, Horizontal cells, Bipolar cells, and Amacrine cells, while the fourth type is the supporting and feeding Muller cells. The presence of these cells is a common characteristic in the retina of all studied birds and vertebrates (Al-Hamdany, 2012 ^[6]; Abid, 2018) ^[3]. This layer appeared to vary in thickness and in the number of its rows between retinal regions. The cells of this layer also differed in size and shape, and this is what appeared in many diurnal birds (Al-Hamdany, 2012 ^[6]; Al- Juburi, 2014) ^[8]. Bipolar cells are a center for transmitting nerve impulses coming from photoreceptor cells, and the dendrites of bipolar cells are connected to the ends of the axons of visual cells, and these cells are similar in birds, reptiles, and amphibians (Abed *et al.*, 2010) ^[2]. Amacrine cells appeared to occupy the lower part of the inner nuclear layer, and amacrine cells direct the lateral interaction of synapses and the transfer of information between adjacent bipolar cells, ganglion and horizontal (Al-Hamdany, 2012) ^[6]. Collin and Collin (1988) indicated that the presence of bipolar cells and amacrine cells in large numbers enhances image differentiation by increasing contrast. Increasing the number of horizontal rows of cells leads to an increase in visual acuity in light, as the upper rows of these cells are linked to cones and the lower ones are linked to rods (De-Juan and ` , 2001) ^[16].

The inner plexiform layer consists of the intertwining that occurs between the projections and axons of cells in the inner nuclear layer with the dendritic projections of ganglion cells in the ganglion cell layer (Mashige and Oduntan, 2016) ^[24]. The results showed that this layer varied in thickness between regions of the retina. The thickness of this layer varied in the different types are due to the density of cells in the outer and inner nuclear layers (Abid, 2018) ^[3]. The thickness of the ganglion cells layer varies among neurons in the retinal regions, as well as the number of their rows, and these differences have appeared in different types of birds (Al-Hamdany, 2012 ^[6]; Al- Juburi, 2014) ^[8]. The difference in the number of rows of ganglion cells in the retina gives clear information about the environment in which the organism lives, enabling it to see objects in the visual field with high visual power (Abdel and Abdel Majeed, 2010) ^[1]. The increase in the density of ganglion cells in a certain area indicates that it is a specialized area, as it gives the power to collect images from different directions at the same time within the visual field, and a high power of discrimination without the need to move the eye, and this indicates that the visual cells are arranged in the same order (Bozzano and Collin, 2000) ^[3].

The nerve fiber layer consists of a grouping of ganglion cell axons, and this layer increases in thickness as it heads toward the formation of the optic nerve that leaves the eye and reaches the brain (Mescher, 2013) ^[25]. The results of the study showed that this layer contains migratory ganglion cells. These cells also appeared in other birds (Abd and Al-Majeed, 2010 ^[1]; Al-Hamdany, 2012) ^[6].

The results showed that the retina in this bird is avascular, that is, it does not contain blood vessels, and thus it differs from the retina of mammals, although a number of mammals lack the retina of blood vessels, as in rabbits and guinea pigs. The avascular retina has appeared in fish, amphibians, and reptiles (Fischer *et al.*, 2010)^[17].

As for retinal specializations, three types of specializations have emerged: fovea, area centralis, the visual streak. These specializations have appeared in the retina of various vertebrates, including birds (Al-Hamdany, 2012^[6]; Abd, 2017). Two fovea have appeared, the first is the dorsotemporal region and the second is in the ventronasal region. The fovea has an important role in increasing the power of vision and noticing the movement of objects, as well as increasing focus towards food (Abdul, 2017). The role of the fovea is also to increase the power of spatial differentiation of the visual field in binocular vision. It also plays an important role in sensing images of moving objects, while the deep fovea acts as adaptive guidance indicators to focus on the direction of the prey (Al-Hamdany, 2012)^[6].

Area centralis appeared in the ventrotemporal region. The area represents an area in which the density of visual cells and ganglion cells increases (Moore *et al.*, 2017)^[29]. The fact that the bird has one area indicates that it searches for its food below eye level (Collin and Ali, 1994), and this is what appeared in this bird.

While one visual streak appeared in the dorsonasal and ventronasal region, the visual streak has appeared in fish, amphibians, reptiles, birds and mammals (Al-Hamdany, 2012^[6]; Moore *et al.*, 2017)^[29]. The visual streak has an important role in preserving flying in the open horizon also contributes to detecting prey on the ground or in the air (Querubin *et al.*, 2009)^[32].

Conclusions

The structure of the retina in this bird indicates its high vision ability and that it is considered an active diurnal bird, due to the presence of more than one type of photoreceptor cells. The thickness of the other layers of the retina indicates the high communication between the retinal cells. In addition to the presence of more than one specialized area in the retina, which clearly indicates the bird's ability to see moving objects and determine their locations, which facilitates the bird's daily living.

References

1. Abd AA, Al-Majeed SA. Anatomical and histological examination of the avian eye in Corncrake (*Crex crex*). *RSsafidain Journal of Science*,2010;21(4):1-26.
2. Abed AA, Ahmed DF, Hamodi HM. Anatomical and histological investigation of the eye structure in the Iraqi pin-tailed sandgrouse bird (*Pterocles alchata caudarus*). *Tikrit Journal of Pure Science*,2010;15(2):109-123.
3. Abid SA. Comparative histological study of the retina in two types of Iraqi vertebrates. *International Journal of Scientific Research*,2018;7(1):656-660.
4. Abid SA. A comparative histological study of the retina in two species of Iraqi vertebrates. *The Iraqi Journal of Agricultural Sciences*,2017;6(48):1573-1581.
5. Al-Arajee HH. Comparative anatomical and histological study of the eyes in three bird species with varying nutritional habits. M.Sc. thesis. University of Mosul, College of Education for Pure Sciences, 2019.
6. Al-Hamdany AM. Comparative anatomical, histological, and developmental study of the eye and alimentary canal in three bird species with different nutrient natures. Ph.D. Thesis. Mosul University, College of Education, 2012. (In Arabic)
7. Ali MA. Histological and histomorphometric study of the retina in pigeon and duck. *Basrah Journal of Veterinary Research*,2016;15(2):260-266.
8. Al-Juburi SA. A comparative phenotypic and histological study of the eye in two types of Iraqi birds (*Falco tinnunculus L.* and *Streptopelia decaocto F.*). M.Sc. Thesis. Baghdad University, College of Sciences for Girls, 2014. (In Arabic)
9. Al-Saqeid M. Birds: Do they see things as we do? *J Harra*,2016;2:57.
10. AlThanoon SA, Taha AM. Histopathological changes in the pregnant rat's lung induced by sodium nitrite and monosodium glutamate. *Iraqi Journal of Veterinary Science*,2022;36(2):419-424.
11. Azab AM, Shoman HM, El-Deeb M, Abdelhafez HM, Abdel Samei SE. Comparative studies on the histology of eye retina in some Nile fishes with different diel activities. *Egyptian Journal of Hospital Medicine*,2017;68:815-823.
12. Bayón A, Almela RM, Talavera J. Avian ophthalmology. *EJCAP*,2007;17(3):253-266.
13. Bozzano A, Collin PS. Retinal ganglion cell topography in Elasmobranchs. *Brain and Behavior*,2000;55:191-208.
14. Collin SP, Collin HB. Topographic analysis of the retinal ganglion cell layer and optic nerve in the sandlance *Limnichthyes fasciatus* (Creeiidae, Perciformes). *Journal of Comparative Neurology*,1988;278:226-241.
15. Collin SP. Specialization of the teleost visual system: Adaptive diversity from shallow-water to deep-sea. *Acta Physiologica Scandinavica*,1997;161:5-24.
16. De-Juan J, Garcia M. Spinules and nematosomes in retinal horizontal cells: a thorny issue. *Progress in Brain Research*,2001;131:165-172.
17. Fischer AJ, Zelinka C, Scott MA. Heterogeneity of glia in the retina and optic nerve of birds and mammals. *PLoS One*,2010;5(6):e10774.
18. Hamid HH, Taha AM. Anatomical and histological structure of the cornea in Sparrowhawk (*Accipiter nisus*). *Iraqi Journal of Veterinary Science*,2021;35(3):437-442.
19. Harmening WM, Wagner H. From optics to attention: visual perception in barn owls. *Journal of Comparative Physiology A*,2011;197(11):1031-1042.
20. Hart NS. Microspectrophotometry of visual pigments and oil droplets in a marine bird, the wedge-tailed shearwater (*Puffinus pacificus*): topographic variations in photoreceptor spectral characteristics. *Journal of Experimental Biology*,2004;207:1229-1240.
21. Jones MP, Pierce KE, Ward D. Avian vision: A comprehensive review of form and function, with

- special emphasis on birds of prey. *Journal of Exotic Pet Medicine*,2007:16(2):69-87.
22. Kardong KV. *Vertebrates Comparative Anatomy, Function, Evolution*. 6th ed. McGraw-Hill,2012:681-690.
 23. Keeling E, Lotery AJ, Tumbarello DA, Ratnayaka JA. Impaired cargo clearance in the Retinal Pigment Epithelium (RPE). *Understanding Irreversible Blindness Diseases*,2018:16:1-19.
 24. Mashige KP, Oduntan OA. A comprehensive review of the human retina, with a focus on nerve fiber layer and macula thicknesses. *African Vision Eye Health*,2016:75(1):1-9.
 25. Mescher AL. *Junqueira's basic histology Text and Atlas*. 13th ed. McGraw Hill,2013:489-494.
 26. Michael W. *Retinal metabolism: A comparative examination of energetics in the retina*. *Brain Research*,2017:1672:50-57.
 27. Mirhish SM, Al-Robaee SJ. Histological study of the pecten oculi and cornea of the falcon's eye ball (*Circus cyaneus c.*). *Iraqi Journal of Veterinary Medicine*,2012:36(1):105-1.
 28. Mitkus M, Olsson P, Toomey MB, Corbo JC, Kelber A. Specialized photoreceptor composition in the raptor fovea. *The Journal of Comparative Neurology*, 2017, 1-12.
 29. Moore BA, Tyrrell LP, Kamilar JM, Collin SP, Dominy NJ, *et al.* Structure and function of regional specializations in the vertebrate retina. In: Kaas J (ed.), *Evolution of Nervous Systems 2e*,2017:351–372.
 30. Moore BA, Yoo I, Tyrrell LP, Benes B, Fernández-Juricic E. FOVEA: A new program to standardize the measurement of foveal pit morphology. *PeerJ*,2016:4:e1785.
 31. Osorio D, Vorobyev M, Jones CD. Colour vision of domestic chicks. *Journal of Experimental Biology*,1999:202:2951–2959.
 32. Querubin A, Lee HR, Provis JM, O'Brien KM. Photoreceptor and ganglion cell topographies correlate with information convergence and high acuity regions in the adult pigeon (*Columba livia*) retina. *Journal of Comparative Neurology*,2009:517(5):711–722.
 33. Rahman ML, Aoyama M, Sugita S. Ganglion cell density and oil droplet distribution in the retina of brown-eared bulbul (*Hypsipetes amaurotis*). *Anatomical Science International*,2008:83:239–246.
 34. Ross MH, Pawlina W. *Histology: A text and atlas with correlated cell and molecular biology*. 6th ed. MPS Limited, A Macmillan,2011:896–927.
 35. Salem MA. Structure and function of the retinal pigment epithelium, photoreceptors, and cornea in the eye of *Sardinella aurita* (Clupeidae, Teleostei). *Journal of Basic and Applied Zoology*,2016:75:1–12.
 36. Suvarna SK, Layton C, Bancroft JD. *Bancroft's theory and practice of histological techniques*. 8th ed. Elsevier, 2019, 234.
 37. Szabadfi KC, Estrada E, Fernandez-Villalba E, Tarragon Jr G, *et al.* Retinal aging in the diurnal Chilean rodent (*Octodon degus*): Histological, ultrastructural, and neurochemical alterations of the vertical information processing pathway. *Frontiers in Cellular Neuroscience*,2015:9:1-14.
 38. Taha AM, Abed AA. The histological and histochemical structure of the rectum in the Cockatiel (*Nymphicus hollandicus*). *Annals of the Royal Society of Cytology and Biology*,2021:25(3):57-67.
 39. Taha AM. Comparative histological and histochemical study of the ileum in two different birds. *Iraqi Journal of Veterinary Science*,2021:35(3):479-487.
 40. Treuting PM, Dintzis SM. *Comparative Anatomy and Histology: A Mouse and Human Atlas*. 1st ed. Elsevier Inc, 2012, 403–405.
 41. Wilby D, Roberts NW. Optical influence of oil droplets on cone photoreceptor sensitivity. *Journal of Experimental Biology*,2017:220:1-8.